

Diagnostic Images

Emphysematous pyelonephritis

Presented by S.H. Siribaddana, C.A. Herath and D.J. Wickramaratne

Renal Unit and Department of Radiology, Sri Jayawardanepura General Hospital, Nugegoda, Sri Lanka

The patient

A 50 year old diabetic woman was admitted with left-sided abdominal pain and fever. She had a temperature of 40°C, pulse pressure of 60 mmHg and a ballotable non-tender lump in the left loin.

Investigations

Plain abdominal X-Ray, erect lateral abdominal X-ray and computerized tomography (CT) of the abdomen.

Discussion

Emphysematous pyelonephritis is a necrotizing renal infection with intrarenal and perirenal gas production.¹ This is primarily encountered in diabetic patients. Severe necrotizing infection and impaired

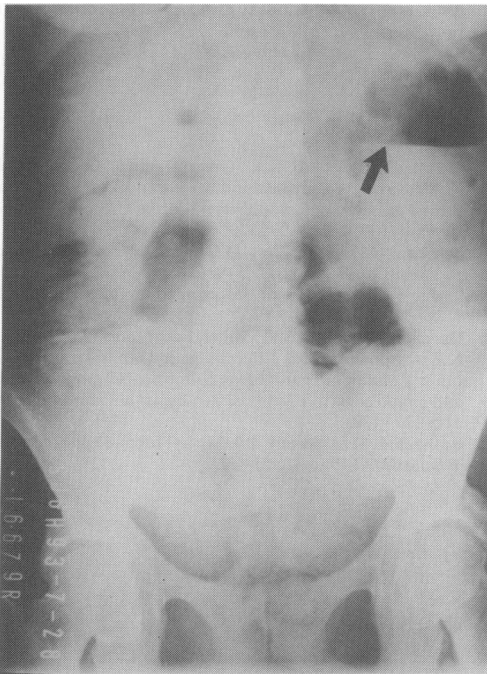


Figure 1 Plain abdominal X-Ray show large left kidney with air fluid level.

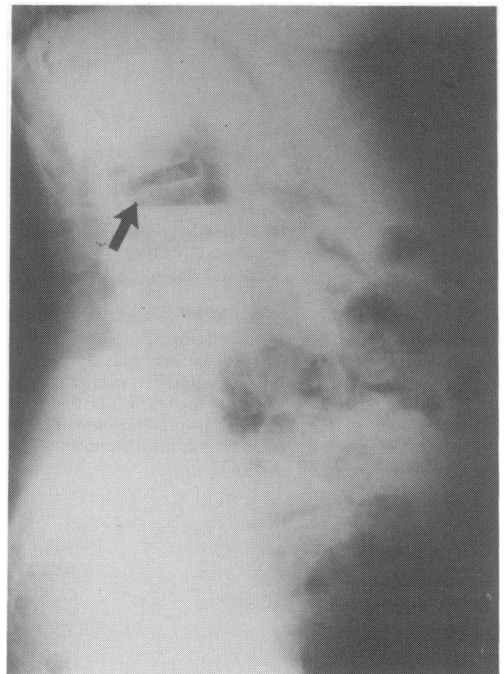


Figure 2 Erect lateral abdominal X-ray shows air shadow, which is posterior to the bowel shadow.

Correspondence: S.H. Siribaddana, M.B.B.S.

Accepted: 31 May 1994

